



## Median Raphe Cysts

### ABSTRACT

Median raphe cysts are rare congenital lesions caused by a defect in embryological development of the male genitalia. They can present as solitary or multiple papules along the median raphe from urethral meatus to the anus. Although they are asymptomatic during childhood, they can cause problems later on as they increase in size. Surgical excision of the lesion is not necessary unless the patient becomes symptomatic.

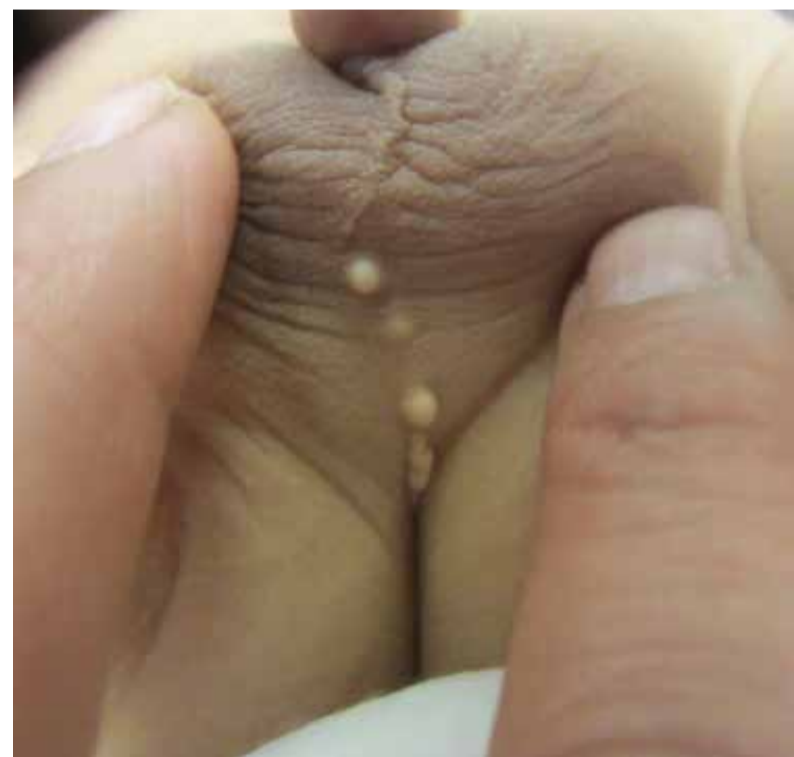**KEYWORDS:** median raphe cysts, congenital lesions, treatment, management



### Case Presentation

A 14 1/2-month-old boy presented with a history of several white papules in the midline of the scrotum and ventral surface of the penis noticed from 3 months of age and possibly since birth. Other than a NICU stay for prematurity and an egg white allergy, he was healthy. Physical examination revealed several white-yellow papules on the midline of his scrotum, and one lesion on the base of his penis [Figure 1]. He had no hypospadias, and no other midline lesions were noted. Based on the site and appearance of the lesions, a diagnosis of median raphe cysts was made.

**Figure 1: Median Raphe Cysts**



### ABOUT THE AUTHORS

Mary Tong, BHS, MD Candidate, McMaster University, Hamilton, ON.

Joseph M Lam, MD, FRCPC, Clinical Associate Professor, Department of Pediatrics, Clinical Associate Professor, Department of Dermatology University of British Columbia, BC.

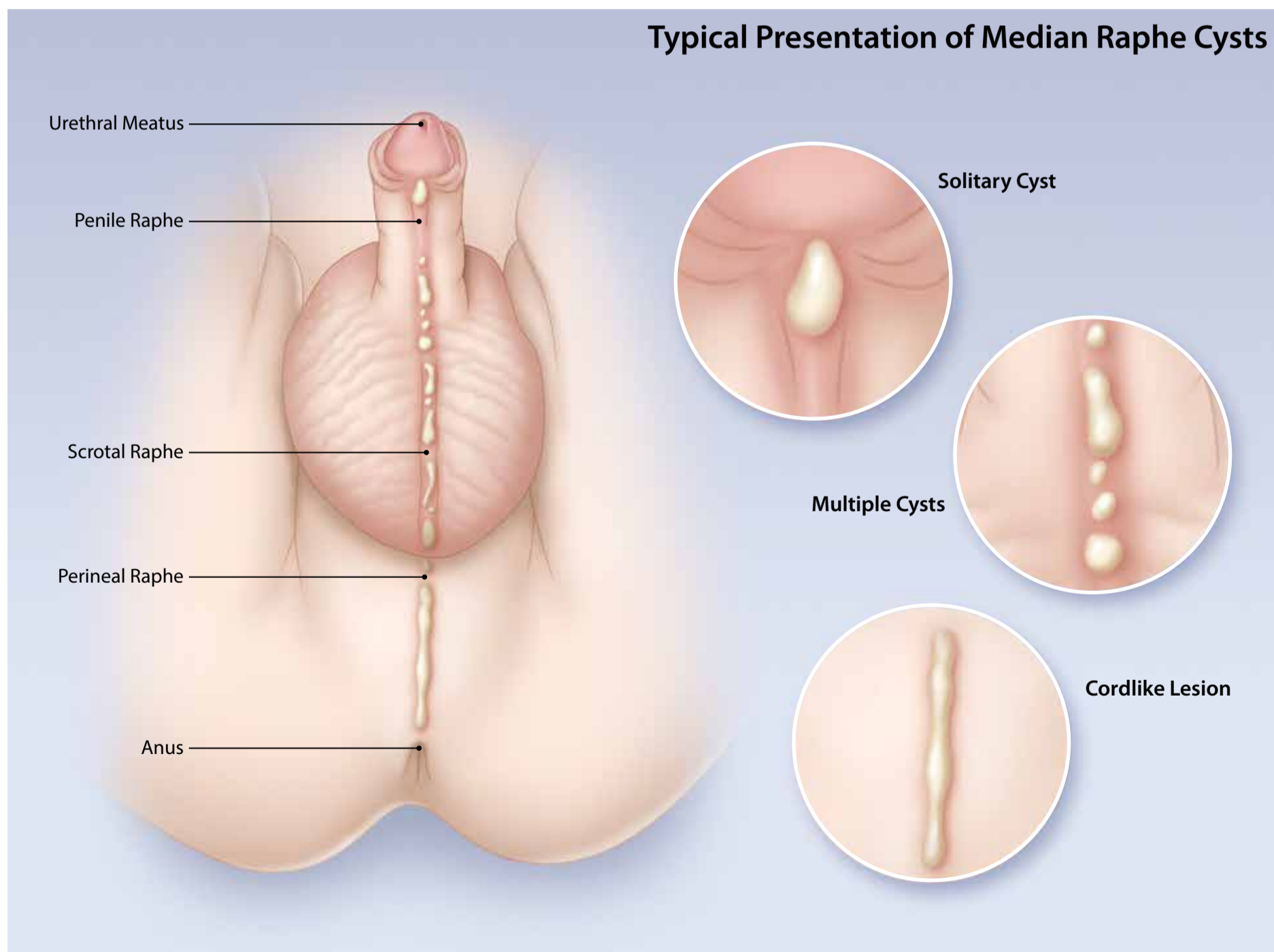


## Discussion

Median raphe cysts are uncommon congenital lesions that were first described in 1895 by Mermet. Other names given to this condition include ‘muroid cyst of penile skin’, ‘parameatal cysts’, ‘apocrine cystadenomas’, ‘genitoperineal cysts’ and ‘urethroid cysts’.<sup>1,2</sup> Less than 30 cases describing pediatric median raphe cysts have been described in the literature.

Median raphe cysts can arise on the ventral midline from the urethral meatus, along the median

raphe of the perineum, to the anus. They can present as a solitary cyst, multiple cysts, or cordlike lesions.<sup>1</sup> Although the pathogenesis of this condition is not well understood, there are theories that may explain the underlying cause. One theory suggests that as the urethral folds fuse and envelope the urethral groove during development, ‘tissue trapping’ occurs and causes an outgrowth of the epithelium. Another theory postulates that the cysts are caused by a defect in the embryological development of the





## SUMMARY OF KEY POINTS

1. Median raphe cysts are benign cysts that can be present at birth, or acquired due to trauma or infection in the genitalia area.
2. Histologically, the cysts can have pseudo stratified columnar, squamous cell, or glandular epithelium, or a mixture of these cells.
3. Although these cysts are asymptomatic during childhood, they should be monitored overtime because they may cause problems as they increase in size with time.
4. Because these are benign malformations, median raphe cysts do not require excision unless they cause problems such as pain, problems with urination or sexual activity, or for cosmetic reasons.

periurethral glands of Littre.<sup>2</sup> There have also been reported cases of acquired median raphe cysts due to incidental trauma, surgical trauma and infection.<sup>1</sup>

Histologically, the lining of the cyst can be with pseudo stratified columnar epithelium, squamous cell epithelium, glandular epithelium, or a mixture of these cells. However, ciliated cells, mucous cells, and melanocytes causing pigmentation have also been reported.<sup>1,2</sup>

In the majority of patients, the cysts are asymptomatic during childhood and may grow over time and cause problems during adolescence and adulthood. The distal cysts are more likely than proximal cysts to be larger and cause issues such as pain, hematuria, or issues with micturition and sexual intercourse. The differential diagnosis of median raphe cysts includes a glomus tumor, dermoid cyst, pilonidal cyst, epidermal inclusion cyst, urethral diverticulum, and steatocystoma.<sup>2</sup>



## CLINICAL PEARLS

Median raphe cysts are benign lesions that may be caused by a defect in the embryological development of the male genitalia.

The differential diagnoses of median raphe cyst include glomus tumor, dermoid cyst, pilonidal cyst, epidermal inclusion cyst, urethral diverticulum, and steatocystoma.

Treatment for asymptomatic median raphe cyst is not necessary but surgical excision can be considered if the cyst is causing problems or for cosmetic reasons.



Because these are benign congenital malformations, if the lesion is asymptomatic, no treatment is necessary. However, surgical interventions can be considered if the cysts become symptomatic (e.g. painful or infected) and/or for cosmetic purposes. The preferred treatment is a complete local excision and only a few surgical complications, such as an urethrocutaneous fistula formation, have been reported.<sup>2</sup>

### References

1. Nishida, H., Kashima, K., Daa, T et al. Pigmented median raphe cyst of the penis. *J Cutan Pathol.* 2012; 39(8):808-810.
2. Amaranathan, A., Sinhasan, SP, Dasiah, SD. Median raphe cysts of the prepuce skin, with triple histological linings: A case report and review of the literature. *J Clin Diagn Res.* 2013; 7(7):1466-1468.

